

Clinical Comparison between the Outcomes of One-Step versus Stepwise Indirect Pulp Capping

Iman Baig^{*1}, Saima Azam²

Islamabad Medical and Dental College, Islamabad

*Corresponding Author: imanbaig99@gmail.com

Keywords: Caries, Dental Pulp Capping, Dental Pulp Exposure, Dental Pulpitis, Pulp Capping

Disclaimers

Author	All authors contributed significantly to this work. Author A designed the study and conducted the
Contributions	data collection, while Author B analysed the data and wrote the manuscript.
Conflict of Interest	The authors declare that there are no conflicts of interest.
Data Availability	Data and supplements available on request to the corresponding author.
Funding	NA
Ethical Approval	Institutional Review Board (IRB) of Islamabad Medical and Dental College (IMDC/DS/IRB/199)
Trial Registration	NA
Acknowledgments	NA

2024 © Open Access. This article is licensed under a Creative Commons Attribution 4.0 International License, which permits use, sharing, adaptation, distribution, and reproduction in any medium or format, with appropriate credit to the original author(s) and source, a link to the license, and an indication of any changes made. If the material is not covered by the license, permission from the copyright holder is required. More details are available at "Creative Commons License".



Published by Link Medical Institute overseen by Link Medical Interface (SMC-PVT) Limited, Pakistan.

Original Article

Clinical Comparison between the Outcomes of One-Step vs. Stepwise Indirect Pulp Capping

Iman Baig, Saima Azam

Abstract

Background: Dental caries is a prevalent disease that can lead to unfavourable pulpal consequences if untreated, making pulp vitality maintenance crucial. Indirect pulp capping is a conservative technique used to support pulp vitality.

Objective: This study aims to clinically compare the outcomes of one-step versus stepwise indirect pulp capping.

Methods: Conducted at the Department of Operative Dentistry of Islamabad Dental Hospital, the study involved 40 patients per group, calculated using the WHO calculator. Convenience sampling selected patients with permanent teeth having 1.5mm-2mm remaining dentin thickness and symptoms of reversible pulpitis. In one-step indirect pulp capping, infected dentin was removed, biocompatible material applied, and the tooth restored with permanent restoration. In stepwise indirect pulp capping, after initial caries removal, soft infected dentin was lined with biocompatible material and temporarily restored. Patients were recalled after 12 weeks for re-entry, and permanent restoration was completed.

Results: SPSS v.22 was used for data analysis. The study included 47.5% male and 52.5% female participants, with a mean age of 29.5 ± 9.05 years. Fisher's exact test showed a significant difference between favourable and unfavourable outcomes between both groups (0.027, $p < 0.05$).

Conclusion: Stepwise indirect pulp capping is a conservative technique that maintains tooth vitality by providing an environment conducive to dentinal bridge formation and pulpal healing.

1 Introduction

Dental caries is a prevalent, though preventable, disease (1). Poor oral care conditions such as caries and periodontal disease result in inflammation and pain, thus negatively impacting individuals' quality of life (2). If caries is left untreated, it will advance into dentine, stimulating pulpitis, which may lead to pulpal infection and necrosis (3). However, if a tooth has a healthy pulpal diagnosis but deep dentine caries, it can be treated, and the vitality of the pulp can be preserved (4, 5). Treatments that preserve pulp vitality are known as vital pulp therapies. One of the vital pulp therapies is indirect pulp capping. It is a conservative management technique that involves removing carious dentine, avoiding pulpal exposure, and treating decay using biocompatible material. The procedure can be done in one step (one-step indirect pulp capping) or two steps (stepwise indirect pulp capping) (4, 6).

One-step indirect pulp capping involves the application of biomaterial onto dentine and the placement of permanent restoration at the same visit (7). In contrast, stepwise indirect pulp capping involves the removal of caries in two appointments. In the first appointment, a temporary restoration is placed over a biomaterial

or protective lining on the dentinal floor. The second appointment is scheduled after 8-12 weeks to remove the remaining carious lesion, followed by the placement of permanent restoration (6, 7).

The biomaterial or protective liner used for the procedure should be capable of promoting reparative or tertiary dentine formation so that pulp vitality is preserved. It should be sterile, radiopaque, and provide a good bacterial seal (8). In comparison to stepwise excavation, single-visit caries excavation is considered an aggressive approach with a higher incidence of pulp exposure (7, 9). When the healthy vital pulp is exposed, it may lead to the seeding of microorganisms in the pulp, thus affecting the prognosis (6).

In stepwise indirect pulp capping, during the first stage, the caries removal and application of biomaterial and temporary restoration provide a favourable environment for developing tertiary dentine (10). Removal of infected dentine and the time between the first and second visits give time for the dentine to proliferate and develop tertiary dentine, which helps maintain the vitality of the pulp (10).

The literature to date has not proven which conservative treatment is better for maintaining the vitality of the tooth (11). Hence, follow-up on conservative management of deep carious lesions will help us gather essential data on prognosis. The objective of this study was to compare the outcome of one-step vs. stepwise indirect pulp capping in teeth with a deep carious lesion at a 6-month follow-up.

2 Material and Methods

This comparative study was conducted at the Department of Operative Dentistry, Islamabad Dental Hospital. A sample size of 40 patients per group was calculated using the WHO calculator with a level of significance at 5%, power of test at 80%, and anticipated success rates for one-step and two-step indirect pulp capping at 0.46 (46.3%) (9) and 0.6 (60.2%) (12), respectively.

Prior to data collection, ethical approval was obtained from the Institutional Review Board (IRB) of Islamabad Medical and Dental College (IMDC/DS/IRB/199). All procedures were conducted following the Declaration of Helsinki. A pre-operative digital radiograph was taken using the paralleling technique with radiograph holders. The remaining dentin thickness (RDT) was measured using the software CSN Image. Permanent teeth with deep carious lesions, RDT between 1.5mm and 2.5mm, and signs and symptoms of reversible pulpitis were included in the study. Teeth exhibiting periapical radiolucency, abscess, pus drainage, pulp exposure during caries removal, root resorption, and calcification were excluded.

Convenience sampling was used for patient selection, and informed consent was obtained from all participants. Local anaesthesia (lignocaine 1:100,000) was administered, and isolation was achieved using a rubber dam. Caries was removed using a slow-speed handpiece with a carbide round bur (RA 04). All cavity walls were cleared, and the floor was inspected for the presence of affected/infected dentin. If affected dentin was present on the floor, a one-step indirect pulp capping procedure was followed. Otherwise, a two-step protocol was implemented. In either procedure, calcium hydroxide was applied to the affected/infected dentin. For the one-step procedure, the tooth was restored with composite restoration at the same visit. For the two-step procedure, an interim restoration (glass ionomer cement) was placed, and the patient was rescheduled after 12 weeks. After 12 weeks, the interim restoration was removed, any remaining infected dentin was removed, and the tooth was permanently restored.

Participants in both groups were recalled for a six-month follow-up. At the follow-up visit, teeth were evaluated clinically and radiographically. Teeth exhibiting signs and symptoms of irreversible pulpitis, pulp necrosis,

and/or periapical involvement were considered to have an unfavourable outcome. The Statistical Package for Social Sciences (SPSS v.22) was used for data analysis. Descriptive statistics for the quantitative variable age were reported. Groups were compared based on pulp vitality, pain, and periapical pathosis using the Fisher Exact test. A p-value ≤ 0.05 was considered statistically significant at a confidence level of 95%.

3 Results

A total of 138 patients were evaluated for eligibility to participate in this study from March 2022 to January 2024. Out of 138 patients, 51 were excluded as 38 patients did not meet the inclusion criteria and 15 refused to take part.

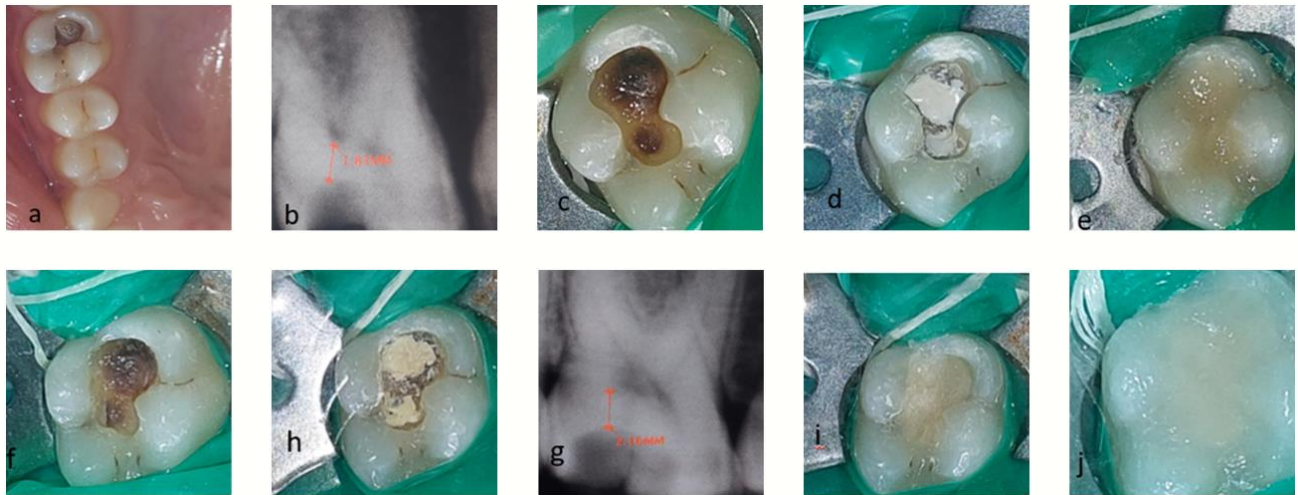


Figure 1 Clinical and radiographic presentation of indirect pulp capping: a) Preoperative clinical picture, b) Preoperative radiograph, c) Soft caries on the floor, d) Dycal application, e) Temporary GIC restoration, f) Re-entry into the cavity, g) Second visit radiograph, h) Dycal application, i) Base GIC application, j) Composite restoration.

The demographic data of gender-wise distribution of patients is shown in Table 1. The mean age and standard deviation were 29.5 ± 9.05 in this study.

Table 1: Distribution based on Gender

Gender	Frequency	Percentage
Male	38	47.5%
Female	42	52.5%

After a six-month follow-up, stepwise indirect pulp capping had a higher success rate at 100% (40) compared to single-visit indirect pulp capping at 87.5% (35).

Table 2: Six Months Follow-up

Outcome	Single Visit Indirect Pulp Capping	Stepwise Indirect Pulp Capping	Total	P-Value
Favorable	35 (87.5%)	40 (100%)	75 (93.75%)	0.027
Unfavorable	5 (12.5%)	0 (0%)	5 (6.25%)	
Total	40	40	80	

In single-visit indirect pulp capping, the unfavourable outcomes that determined the failure of the treatment included pain at 12.5% (n=5), tenderness to percussion at 12.5% (n=5), radiolucency at 2.5% (n=1), and PDL widening at 12.5% (n=5). At follow-up, Fisher's exact test showed a significant difference between both groups (0.027, $p < 0.05$) as shown in Table 2.

4 Discussion

The primary aim of dental treatment is the preservation of the vitality of the tooth. Bacteria within dental plaque and caries act as driving forces for pulpal inflammation. The extent of removal of the carious lesion remains an important concern while aiming to maintain pulp vitality; therefore, it has become an important research question (13). Stepwise excavation provides a solution to this problem. It removes infected dentin and seals the cavity, providing time for the pulp to heal and develop tertiary dentin. It helps reduce iatrogenic exposure and preserves the vitality of the pulp (14, 15).

Stepwise indirect pulp capping showed better results at 100% (40) compared to single-visit indirect pulp capping at 87.5% (35). These results are similar to the findings of the study conducted by Leksell et al. (16). In this study, patients were recalled at an interval of 12 weeks for the second visit of stepwise indirect pulp capping, as Al Orhan et al. mentioned that a treatment interval of 8-12 weeks is sufficient for tertiary dentin formation (16). For stepwise indirect pulp capping, at re-entry, soft, leathery dentin changes into a darker, harder, and drier surface as defined by Miller and Masseler (17, 18). The Maillard reaction can be responsible for the arresting of caries and the dark discoloration of dentin (19). Therefore, a proper seal of the cavity with bioactive material can help in the development of tertiary dentin and play a role in maintaining pulp vitality (20).

When both groups were compared for the primary outcome success, i.e., sustained vitality after the follow-up period, stepwise indirect pulp capping had a higher success rate than single-visit indirect pulp capping. The success of stepwise indirect pulp capping coincides with the study conducted by Dholani et al. (21). Besides other clinical evidence, a decrease in bacterial load after stepwise excavation was found (16). Thus, a decrease in bacterial load can be one of the main reasons for achieving favourable outcomes in stepwise indirect pulp capping compared to single-visit indirect pulp capping. In this study, for single-visit indirect pulp capping, 12.5% of patients experienced pain, 12.5% had tenderness to percussion, 2.5% had radiolucency, and 12.5% had widening of the PDL.

In two-step indirect pulp capping, at the final stage of excavation, no pulpal exposure was experienced, aligning with the study by Bjorndal et al. (14). Stepwise indirect pulp capping is a pain-free procedure and can be used among children as the administration of local anaesthesia can be avoided (18). Most previous studies did not mention the depth of the carious lesion. However, in this study, similar to Bjorndal et al. (12), specific depths of carious lesions were considered as inclusion and exclusion criteria for the tooth. In both groups, preoperative clinical and radiographic assessments were carried out to ensure comparable baselines. The limitation of this study was the lack of microbiological and histological assessment to support the clinical parameters. However, the use of rubber dams and adherence to the same protocol for procedures and restorations improved the quality of the study and reduced performance bias.

5 Conclusion

Stepwise indirect pulp capping produces better results compared to one-step indirect pulp capping. Stepwise excavation reduces the chances of pulp exposure. Re-entry does not cause pulpal exposure. The interval time provides an opportunity to produce secondary dentin and helps maintain pulp vitality. This procedure is painless due to the reduced need for local anaesthesia, making it suitable for children or patients with dental phobia.

References

1. World Health O. Sugars and dental caries. Geneva: World Health Organization; 2017 2017. Contract No.: WHO/NMH/NHD/17.12.
2. Clarkson JE, Ramsay CR, Ricketts D, Banerjee A, Deery C, Lamont T, et al. Selective Caries Removal in Permanent Teeth (SCRiPT) for the treatment of deep carious lesions: a randomized controlled clinical trial in primary care. *BMC Oral Health*. 2021;21(1):336.
3. Bjørndal L, Simon S, Tomson PL, Duncan HF. Management of deep caries and the exposed pulp. *Int Endod J*. 2019;52(7):949-73.
4. Gurcan AT, Seymen F. Clinical and radiographic evaluation of indirect pulp capping with three different materials: a 2-year follow-up study. *EJPD*. 2019;20/2-2019(2035-648X (Electronic)):105-10.
5. Fagundes TC, Barata TJE, Prakki A, Bresciani E, Pereira JC. Indirect pulp treatment in a permanent molar: case report of 4-year follow-up. *J Appl Oral Sci*. 2009;17(1):70-4.
6. Hoefler V, Nagaoka H, Miller CS. Long-term survival and vitality outcomes of permanent teeth following deep caries treatment with step-wise and partial-caries-removal: A Systematic Review. *J Dent*. 2016;54:25-32.
7. Duncan HF, Galler KM, Tomson PL, Simon S, El-Karim I, Kundzina R, et al. European Society of Endodontology position statement: Management of deep caries and the exposed pulp. *Int Endod J*. 2019;52(7):923-34.
8. Nair M, Gurunathan D. Clinical and Radiographic Outcomes of Calcium Hydroxide vs Other Agents in Indirect Pulp Capping of Primary Teeth: A Systematic Review. *Int J Clin Pediatr Dent*. 2019;12(5):437-44.
9. Bjørndal L, Fransson H, Bruun G, Markvart M, Kjældgaard M, Näsman P, et al. Randomized Clinical Trials on Deep Carious Lesions: 5-Year Follow-up. *J Dent Res*. 2017;96(7):747-53.
10. Bjørndal L. Stepwise Excavation. *Monogr Oral Sci*. 2018;27:68-81.
11. Alsadat F, El-Housseiny A, Alamoudi N, Alnowaiser A. Conservative treatment for deep carious lesions in primary and young permanent teeth. *Niger J Clin Pract*. 2018;21(12):1549-56.
12. Bjørndal L, Reit C, Bruun G, Markvart M, Kjældgaard M, Näsman P, et al. Treatment of deep caries lesions in adults: randomized clinical trials comparing stepwise vs. direct complete excavation, and direct pulp capping vs. partial pulpotomy. *Eur J Oral Sci*. 2010;118(3):290-7.
13. Kidd EAM. How 'Clean' Must a Cavity Be before Restoration? *Caries Res*. 2004;38(3):305-13.
14. Bjørndal L, Larsen T Fau - Thylstrup A, Thylstrup A. A clinical and microbiological study of deep carious lesions during stepwise excavation using long treatment intervals. *Caries Res*. 1997;31(6)(0008-6568 (Print)):411-7.
15. Diana Trifan DU. Single visit indirect pulp capping with Biodentine: clinical case report. *Mold J Health Sci* 2024;11(1):72-6.

16. Orhan AI, Oz Ft Fau - Ozcelik B, Ozcelik B Fau - Orhan K, Orhan K. A clinical and microbiological comparative study of deep carious lesion treatment in deciduous and young permanent molars. *Clin Oral Investig.* 2008;12(4)(1436-3771 (Electronic)):369-78.
17. Lehmann M, Veitz-Keenan A, Matthews AG, Vena D, Grill A, Craig RG, et al. Dentin caries activity in early occlusal lesions selected to receive operative treatment. *J Am Dent Assoc.* 2012;143(4):377-85.
18. Manhas S, Pandit IK, Gugnani N, Gupta M. Comparative Evaluation of the Efficacy of Stepwise Caries Excavation vs Indirect Pulp Capping in Preserving the Vitality of Deep Carious Lesions in Permanent Teeth of Pediatric Patients: An In Vivo Study. *Int J Clin Pediatr Dent.* 2020;13 (Suppl 1)(0974-7052 (Print)):S92-S7.
19. Al-Asmar AA, Al-Hiyasat AS, Pitts NB. Reframing perceptions in operative dentistry relating evidence-based dentistry and clinical decision making: a cross-sectional study among Jordanian dentists. *BMC Oral Health.* 2022;22(1).
20. Baig I, Mushtaq TB. Ways of Maintaining Pulp Vitality: Narrative Literature Review. *Journal of Health and Rehabilitation Research.* 2024;4(1):1763-7.
21. Dholani JI, Chokshi SP, Sanghvi ZK, Menon SS. Stepwise caries intervention: An approach precursive to endodontic intervention – A case series. *SEJ.* 2024;14(2).

~ JHRR, ISSN: 2791-156X ~